

# Iliotibial Band Syndrome: A Common Source of Knee Pain

RAZIB KHAUND, M.D., *Brown University School of Medicine, Providence, Rhode Island*  
SHARON H. FLYNN, M.D., *Oregon Medical Group/Hospital Service, Eugene, Oregon*

Iliotibial band syndrome is a common knee injury. The most common symptom is lateral knee pain caused by inflammation of the distal portion of the iliotibial band. The iliotibial band is a thick band of fascia that crosses the hip joint and extends distally to insert on the patella, tibia, and biceps femoris tendon. In some athletes, repetitive flexion and extension of the knee causes the distal iliotibial band to become irritated and inflamed resulting in diffuse lateral knee pain. Iliotibial band syndrome can cause significant morbidity and lead to cessation of exercise. Although iliotibial band syndrome is easily diagnosed clinically, it can be extremely challenging to treat. Treatment requires active patient participation and compliance with activity modification. Most patients respond to conservative treatment involving stretching of the iliotibial band, strengthening of the gluteus medius, and altering training regimens. Corticosteroid injections should be considered if visible swelling or pain with ambulation persists for more than three days after initiating treatment. A small percentage of patients are refractory to conservative treatment and may require surgical release of the iliotibial band. (*Am Fam Physician* 2005;71:1545-50. Copyright© American Academy of Family Physicians.)

See page 1465 for strength-of-evidence labels.

**Iliotibial band syndrome is a common knee injury that usually presents as lateral knee pain caused by inflammation of the distal portion of the iliotibial band.**

Iliotibial band syndrome is a common knee injury that usually presents as lateral knee pain caused by inflammation of the distal portion of the iliotibial band; occasionally, however, the iliotibial band becomes inflamed at its proximal origin and causes referred hip pain. The iliotibial band is a thick band of fascia that is formed proximally by the confluence of fascia from hip flexors, extensors, and abductors. The band originates at the lateral iliac crest and extends distally to the patella, tibia, and biceps femoris tendon (*Figure 1*).<sup>1</sup>

Iliotibial band syndrome occurs frequently in runners or cyclists, and is caused by a combination of overuse and biomechanical factors. The syndrome can cause significant morbidity; however, most patients respond to a conservative treatment approach that involves stretching and altering training regimens.

## Etiology

Iliotibial band syndrome is caused by excessive friction of the distal iliotibial band as

it slides over the lateral femoral epicondyle during repetitive flexion and extension of the knee resulting in friction and potential irritation. In patients with iliotibial band syndrome, magnetic resonance imaging (MRI) studies have shown that the distal iliotibial band becomes thickened and that the potential space deep to the iliotibial band over the femoral epicondyle becomes inflamed and filled with fluid.<sup>2</sup>

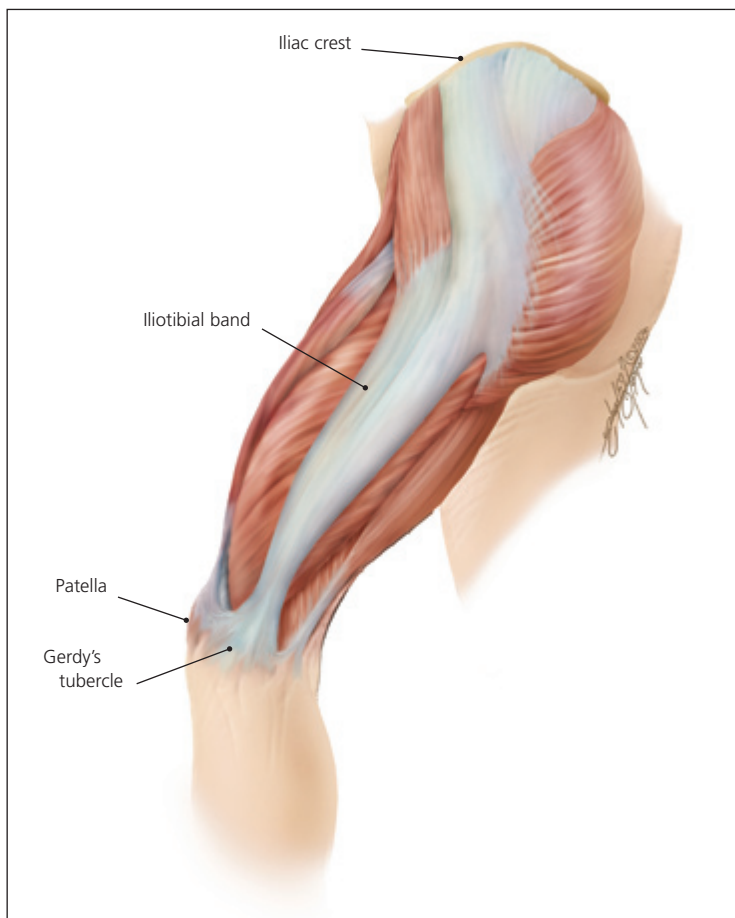
Despite a clear pathophysiology, it is unclear why this syndrome does not affect all athletes. Few studies<sup>3-7</sup> have shown any direct relationship between biomechanical factors and the development of iliotibial band syndrome. Excessive pronation causing tibial internal rotation and increased stress in the iliotibial band was believed to be a factor in the development of iliotibial band syndrome; however, the literature does not support this theory.

Some observational studies<sup>4,6</sup> have identified potential risk factors for the development of iliotibial band syndrome, including the following: preexisting iliotibial band tightness; high weekly mileage; time spent walking or running on a track; interval training; and muscular weakness of knee

## Strength of Recommendations

Key clinical recommendation	Label	References
Hip abductor weakness seems to contribute to the development of iliotibial band syndrome. Strengthening of the hip abductors has led to symptom improvement.	B	6
Strength training should be an integral part of any runner's regimen; however, for patients with iliotibial band syndrome particular emphasis needs to be placed on the gluteus medius muscle.	B	6
The stretch seen in Figure 4C was consistently the most effective in increasing the length of the iliotibial band in a study of elite distance runners.	B	9
In a retrospective study of 45 patients who underwent surgical release of their iliotibial band, 84 percent of the patients reported that their surgery result were good to excellent.	B	10

A = consistent, good-quality patient-oriented evidence; B = inconsistent or limited-quality patient-oriented evidence; C = consensus, disease-oriented evidence, usual practice, opinion, or case series. See page 1465 for more information.



**FIGURE 1.** The iliotibial band is a thick band of fascia that extends along the lateral thigh from the iliac crest to the knee.

extensors, knee flexors, and hip abductors. Hip abductor weakness seems to contribute to the development of iliotibial band syndrome. Strengthening of the hip abductors has led to symptom improvement.<sup>6</sup>

### Clinical Presentation

The primary initial complaint in patients with iliotibial band syndrome is diffuse pain over the lateral aspect of the knee. These patients frequently are unable to indicate one specific area of tenderness, but tend to use the palm of the hand to indicate pain over the entire lateral aspect of the knee. With time and continued activity, the initial lateral achiness progresses into a more painful, sharp, and localized discomfort over the lateral femoral epicondyle and/or the lateral tibial tubercle. Typically, the pain begins after the completion of a run or several minutes into a run; however, as the iliotibial band becomes increasingly irritated, the symptoms typically begin earlier in an exercise session and can even occur when the person is at rest. Patients often note that the pain is aggravated while running down hills, lengthening their stride, or sitting for long periods of time with the knee in the flexed position.<sup>7</sup> The differential diagnosis for lateral knee pain is listed in *Table 1*.

TABLE 1  
Differential Diagnosis  
of Lateral Knee Pain

Biceps femoris tendinopathy
Degenerative joint disease
Lateral collateral ligament sprain
Lateral meniscal tear
Myofascial pain
Patellofemoral stress syndrome
Popliteal tendinopathy
Referred pain from lumbar spine
Stress fracture
Superior tibiofibular joint sprain

### Physical Examination

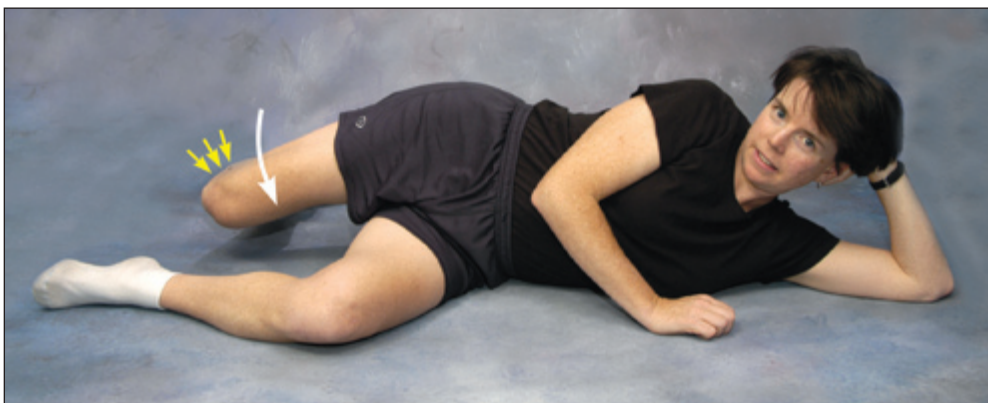Patients with iliotibial band syndrome often demonstrate tenderness on palpation of the lateral knee approximately 2 cm above the joint line. Tenderness frequently is worse when the patient is in a standing position and the knee is flexed to 30 degrees. At this angle, the iliotibial band slides over the femoral condyle and is at maximal stress, thus reproducing the patient's symptoms.<sup>1,6</sup> Swelling may be noted at the distal iliotibial band and thorough palpation of the affected limb may reveal multiple trigger points in the vastus lateralis, gluteus medius, and biceps femoris. Palpation of these trigger points may cause referred pain to the lateral aspect of the affected knee. Strength of the

lower extremity should be assessed with particular emphasis on examining the knee extensors, knee flexors, and hip abductors. Weakness in these muscle groups has been associated with the development of iliotibial band syndrome.<sup>4,6,7</sup>

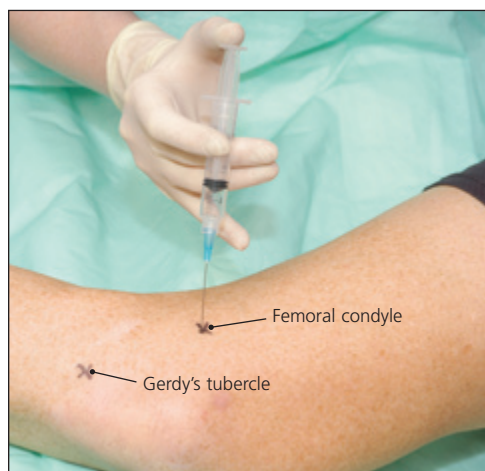
The Ober's test can be used to assess tightness of the iliotibial band (*Figure 2*). With the patient lying on the side with the unaffected side down and the unaffected hip and knee at a 90-degree angle, the examiner stabilizes the pelvis, then abducts and extends the affected leg until it is aligned with the rest of the patient's body. The affected leg is lowered into adduction. If the iliotibial band is normal in length and unaffected, the leg will adduct and the patient will not experience pain. If the iliotibial band is tight, the leg will remain in the abducted position and the patient may have lateral knee pain.<sup>1,6,8</sup> A tight iliotibial band contributes to the excess friction placed on the iliotibial band as it slides over the femoral condyle during flexion and extension of the knee.

A clinical diagnosis is based on the history and physical examination. If the diagnosis is in doubt or other joint pathology is suspected, MRI can aid in the diagnosis and provide additional information about patients considered for surgery. In patients with iliotibial band syndrome, MRI shows a thickened ilio-

**If the iliotibial band is tight, the leg will remain in the abducted position and the patient may have lateral knee pain when Ober's test is conducted.**



**FIGURE 2.** Ober's test. The patient lies down with the unaffected side down and the unaffected hip and knee at a 90-degree angle. If the iliotibial band is tight, the patient will have difficulty adducting the leg beyond the midline and may experience pain at the lateral knee (arrows).



**FIGURE 3.** Corticosteroid injection for iliotibial band syndrome. Gerdy's tubercle and the femoral condyle are marked as landmarks. With the patient in a supine or side-lying position, the needle is inserted at the point of maximum tenderness over the femoral condyle.

tibial band over the lateral femoral epicondyle and often detects a fluid collection deep to the iliotibial band in the same region.<sup>2</sup>

### Treatment

Treatment requires activity modification, massage, and stretching and strengthening of the affected limb. The goal is to minimize the friction of the iliotibial band as it slides over the femoral condyle. The patient may be referred to a physical therapist who is trained in treating iliotibial band syndrome. Most runners with low mileage respond to a

regimen of anti-inflammatory medicines and stretching; however, competitive or high-mileage runners may need a more comprehensive treatment program.

The initial goal of treatment should be to alleviate inflammation by using ice and anti-inflammatory medications. Patient education and activity modification are crucial to successful treatment. Any activity that requires repeated knee flexion and extension is prohibited. During treatment, the patient may swim to maintain cardiovascular fitness. If visible swelling or pain with ambulation persists for more than three days after initiating treatment, a local corticosteroid injection should be considered<sup>6</sup> (Figure 3).

As the acute inflammation diminishes, the patient should begin a stretching regimen that focuses on the iliotibial band as well as the hip flexors and plantar flexors. The common iliotibial band stretches (Figure 4) have been evaluated for their effectiveness in stretching the band. The stretch shown in Figure 4C was consistently the most effective in increasing the length of the iliotibial band in a study<sup>9</sup> of elite distance runners. Although this study<sup>9</sup> demonstrates the effectiveness of stretching the iliotibial band, participants in the study did not have iliotibial band syndrome and studies have not demonstrated that stretching hastens recovery from the syndrome.

Once the patient can perform stretching without pain, a strengthening program should be initiated. Strength training should be an integral part of any runner's regimen; however, for patients with iliotibial band syndrome particular emphasis needs to be placed on the gluteus medius muscle.<sup>6</sup> A strengthening exercise geared toward the gluteus medius is shown in Figure 5.

Running should be resumed only after the patient is able to perform all of the strength exercises without pain. The return to running should be gradual, starting at an easy pace on a level surface. If the patient is able to tolerate this type of running without pain, mileage can be increased slowly. For the first week, patients should run only every other day, starting with easy sprints on a level surface. Most patients improve within three

### The Authors

RAZIB KHAUND, M.D., is clinical assistant professor of medicine in the Department of Orthopedic and Internal Medicine at Brown University School of Medicine, Providence, R.I., a physician in internal medicine at the Hughston Clinic in Columbus, Georgia, and a sports medicine specialist at the New England Center for Athletes in Providence. Dr. Khaund received his medical degree from New Jersey Medical University, Newark. He completed a fellowship in sports medicine at the Hughston Clinic.

SHARON H. FLYNN, M.D., is a hospitalist at the Oregon Medical Group/Hospital Service, Eugene, Ore., and has a special interest in sports medicine. She received her medical degree from George Washington University Medical Center, Washington, D.C., and completed a residency in internal medicine at Rhode Island Hospital/Brown University School of Medicine.

Address correspondence to Sharon H. Flynn, M.D., Oregon Medical Group/Hospital Service, 1200 Hilyard St., Suite S-140, Eugene, OR 97401 (e-mail: sflynn@peacehealth.org). Reprints are not available from the authors.



FIGURE 4. Stretches of the right iliotibial band.

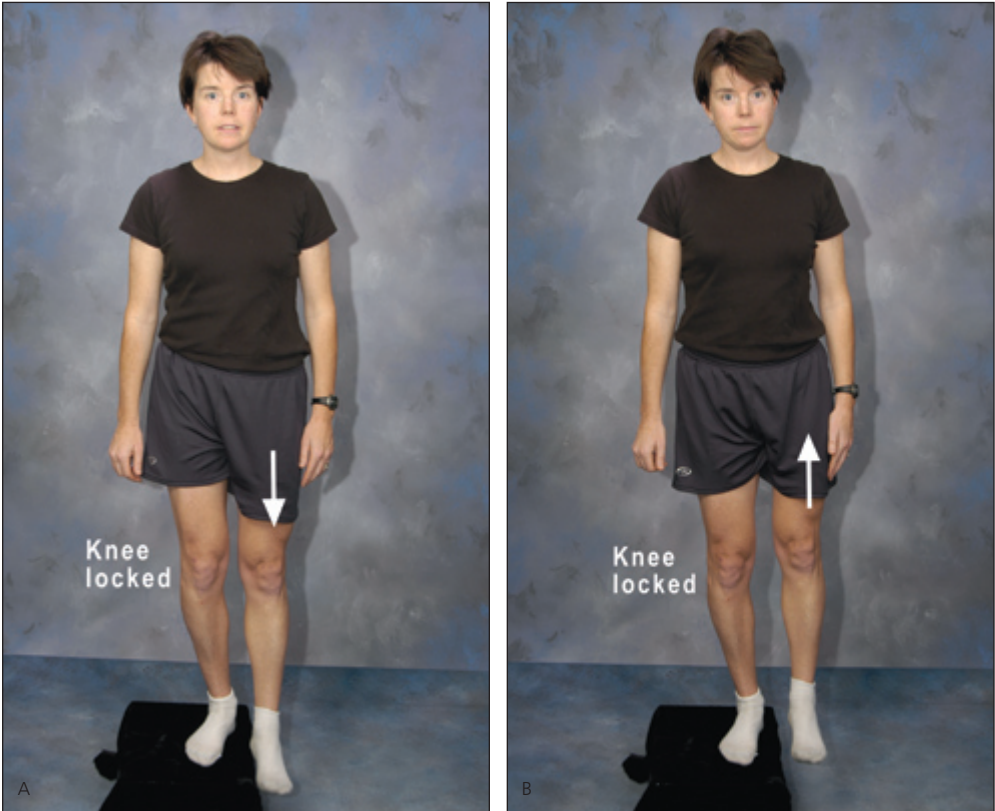

FIGURE 5. Exercise for strengthening of the right gluteus medius muscle in a weight-bearing position. (A) The patient stands on a platform and lowers the left leg toward the ground slowly. (B) Through contraction of the right gluteus medius, the patient then elevates the leg, returning the pelvis to a level position.

## Iliotibial Band Syndrome

to six weeks if they are compliant with their stretching and activity limitations.<sup>1</sup>

For patients who do not respond to conservative treatment, surgery should be considered. The most common approach is to release the posterior 2 cm of the iliotibial band where it passes over the lateral epicondyle of the femur. In a retrospective study<sup>10</sup> of 45 patients who underwent surgical release of their iliotibial band, 84 percent of the patients reported that their surgery results were good to excellent.

The authors indicate that they do not have any conflicts of interest. Sources of funding: none reported.

Figures 2 through 5 used with permission from Sharon H. Flynn, M.D.

---

### REFERENCES

1. Panni AS, Biedert RM, Maffulli N, Tartarone M, Romagnoli E. Overuse injuries of the extensor mechanism in athletes. *Clin Sports Med* 2002;21:483-98.
2. Ekman EF, Pope T, Martin DF, Curl WW. Magnetic resonance imaging of iliotibial band syndrome. *Am J Sports Med* 1994;22:851-4.
3. Taunton JE, Ryan MB, Clement DB, McKenzie DC, Lloyd-Smith DR, Zumbo BD. A retrospective case-control analysis of 2002 running injuries. *Br J Sports Med* 2002;36:95-101.
4. Messier SP, Edwards DG, Martin DF, Lowery RB, Cannon DW, James MK, et al. Etiology of iliotibial band friction syndrome in distance runners. *Med Sci Sports Exerc* 1995;27:951-60.
5. Messier SP, Pittala KA. Etiologic factors associated with selected running injuries. *Med Sci Sports Exerc* 1988;20:501-5.
6. Fredericson M, Cookingham CL, Chaudhari AM, Dowdell BC, Oestreicher N, Sahrmann SA. Hip abductor weakness in distance runners with iliotibial band syndrome. *Clin J Sport Med* 2000;10:169-75.
7. Orchard JW, Fricker PA, Abud AT, Mason BR. Biomechanics of iliotibial band friction syndrome in runners. *Am J Sports Med* 1996;24:375-9.
8. Fredericson M, Guillet M, DeBenedictis L. Quick solutions for iliotibial band syndrome. *Phys Sportsmed* 2000;28:53-68.
9. Fredericson M, White JJ, Macmahon JM, Andriacchi TP. Quantitative analysis of the relative effectiveness of 3 iliotibial band stretches. *Arch Phys Med Rehabil* 2002;83:589-92.
10. Drogset JO, Rossvoll I, Grontvedt T. Surgical treatment of iliotibial band friction syndrome. A retrospective study of 45 patients. *Scand J Med Sci Sports* 1999;9:296-8.